

THE TAMIL NADU DR. AMBEDKAR LAW UNIVERSITY



AUTOPSY VISIT REPORT

SUBMITTED TO

THE TAMIL NADU DR. AMBEDKAR LAW UNIVERSITY

CRIMINAL LAW AND CRIMINAL JUSTICE ADMINISTRATION

BATCH: 2020 – 2022

THE TAMILNADU DR. AMBEDKAR LAW UNIVERSITY

POOMPOZHIL, #5 GREENWAYS ROAD, CHENNAI –

600 028

- 1) DATE OF VISIT: 29/06/2022
- 2) TIME: 10 AM TO 2 PM
- 3) PLACE: KILPAUK MEDICAL COLLEGE AND HOSPITAL
- 4) MEMBERS PRESENT:
 - 1) Dr. S. Raja Lakshmi (Head of the Department, Criminal law)
 - 2) MuthuKrishnan (Guest Faculty)
 - 3) Tiruveni (Guest Faculty)
 - 4) Priya Dharshini (Guest Faculty)

STUDENTS

- 1) A. Keerthana
- 2) Janaki Priya
- 3) Reshma John
- 4) Jeevitha
- 5) Sajithra
- 6) Deepa
- 7) Anjana Lakshmi
- 8) Sandhiya
- 9) Hari Priya
- 10) Hari Krishnan
- 11) Siranjeevi
- 12) Adhi Karthikeyan
- 13) Nagarjuna
- 14) Mathanachandiran

OBSERVATION

We were taken to Kilpauk Medical college Hospital to observe Autopsy as a part of our learning for the subject Criminalistic and Scientific Investigation. We have already learnt the theoretical aspect of Autopsy in classroom and now got an opportunity to practically see the process. Once we went to the college, we were taken to the Department of Forensic Medicine. There we had an opportunity to see the preserved specimens of various body parts. Once we observed the Specimens, we had a mam from the Department explain some of the Specimens. There were specimens of Foetus, Brain Haemorrhage, Cardiomegaly, Splenomegaly, Skulls, Bones, Murder Weapons, and Reptile (Toxicology). There were photographs of people died due to different causes like Electrocutation, Hanging, Runover by Vehicle, Bullet injury, Poisoning, Beheading etc. Some of the images have been attached below. Then we had an interaction with Dr Sathish Kumar. We asked our doubts regarding the Specimens over there and he explained each of our Question with absolute clarity. Then we had an interaction with the Head of the Department (Department of Forensic Medicine) in a room nearby. He shared his experience in some prominent cases like Ramkumar Autopsy Case and recent Custodial Death case. He discussed the importance of Forensic Science in Criminal Justice Administration. He gave an idea as to what is the job of a Forensic Doctor and what exactly he will be doing. He emphasized on the need to have a better Cross Examination in Courts for Forensic Science experts.

Then we were taken to the Hospital (Mortuary) which was opposite to the College. Once we entered the Mortuary, we were taken inside the room where Autopsy takes place. We were not allowed to take video or Picture of the process. The Subject of the Autopsy we witnessed was dead in a Train Accident few hours before we arrived there (approx. 4 hours). The face of the dead body was smashed to an extent that the face was not clearly visible. Nose was disassociated from face but was slightly attached and the eyes were severely damaged. It should be due to the force of the hit. There were 3 diener¹ and one Doctor (Dr. Sathish Kumar). Once we all got assembled in the room, the Doctor started to interact with us. He gave a clear idea about,

- 1) What is Autopsy?
- 2) Why is it done?
- 3) When it is done?
- 4) What is meant by Medico Legal Cases?

¹ A diener is a morgue worker responsible for handling, moving, and cleaning the corpse.

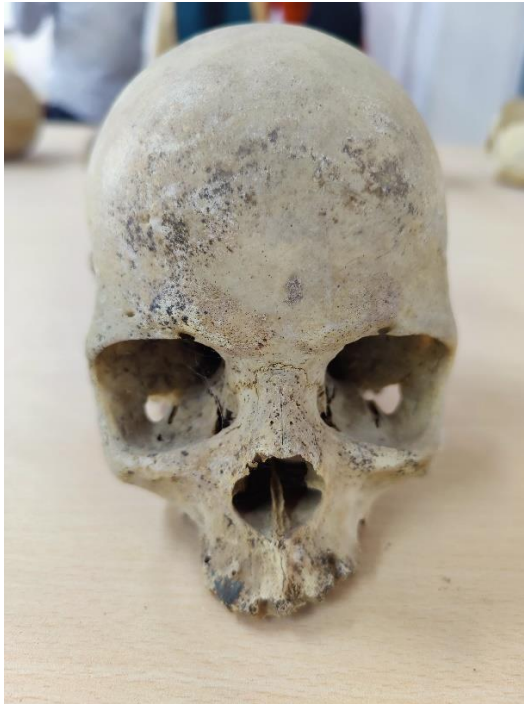- 5) What is the role of Autopsy in proving or disproving a case?
- 6) What the Procedure for doing an Autopsy?
- 7) How to appreciate the minor differences in Suicidal and Homicidal cases.

We had a detailed interaction regarding the above-mentioned topics which gave us a clear perspective as to what happens there. Then the Diener started doing Autopsy on command of the Doctor. The process took place in the following manner,

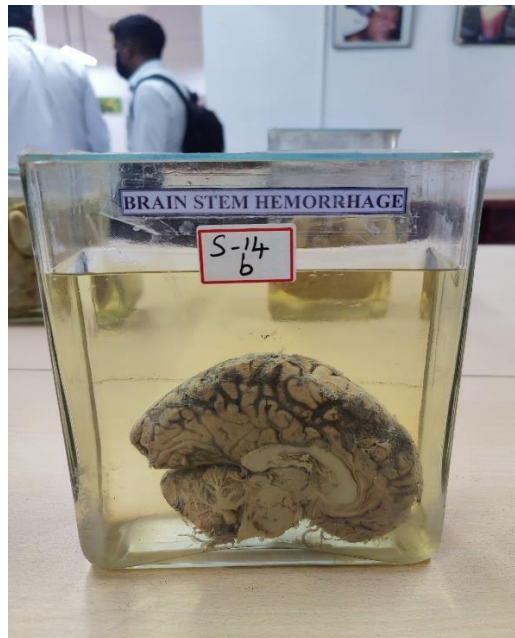
- 1) The dress of the Dead Body was torn off and taken away, the body was in a Rigor Mortis stage and was stiff to handle;
- 2) The body was washed with water;
- 3) Then the wounds in the Dead Body were measured by the diener as the Doctor kept noting it;
- 4) Then scalp was torn in the middle and was completely torn off;
- 5) Then the skull was broken off by the diener and the brain was taken out;
- 6) There was a haemorrhage in the Brain and the Doctor said that in itself is a cause of Death;
- 7) Then with a small knife, the body was torn from the neck till the stomach;
- 8) The Rib was torn off;
- 9) Then the Organs from the food pipe till intestine were taken off at once;
- 10) Each organ was cut and Doctor explained us as to which organ should be examined in case of what kind of Death;
- 11) Then all the Organs were kept inside the Body again;
- 12) Doctor concluded the cause of Death to be skull injury and Brain Haemorrhage;
- 13) Then the Documents regarding the Autopsy procedure was explained by the Doctor.

We learnt how the process is done and how important it is in Criminal Justice Administration. We also learnt how the role of the Investigating officer is crucial in a criminal case. On the whole, it was a good learning experience and we would like to thank the HOD (Dr. S. Raja Lakshmi) and the University for providing us with an opportunity like this.

PICTURES



A) Picture of a Human Skull



B) Picture of Brain Hemorrhage



C) Forensic Toxicology



D) Skulls and Bones





E) Images taken during Interaction



F) Group Picture with the Head of Department of the Department of Forensic Medicine



G) Class Group Picture